

Artery Research

ISSN (Online): 1876-4401

ISSN (Print): 1872-9312

Journal Home Page: <https://www.atlantis-press.com/journals/artres>

P2.05: INVESTIGATION OF FLOW AND WALL SHEAR STRESS DURING PULSATILE FLOW IN A HUMAN AORTA WITH A COARCTATION AND POST-STENOTIC DILATATION USING LARGE EDDY SIMULATIONS

R. Gårdhagen, M. Karlsson

To cite this article: R. Gårdhagen, M. Karlsson (2012) P2.05: INVESTIGATION OF FLOW AND WALL SHEAR STRESS DURING PULSATILE FLOW IN A HUMAN AORTA WITH A COARCTATION AND POST-STENOTIC DILATATION USING LARGE EDDY SIMULATIONS, Artery Research 6:4, 164–165, DOI: <https://doi.org/10.1016/j.artres.2012.09.086>

To link to this article: <https://doi.org/10.1016/j.artres.2012.09.086>

Published online: 21 December 2019

Nevertheless, CBP can be calculated with echotracking at the common carotid artery (CCA) assuming the fact that the distension waveform is similar to a pressure curve.

Objectives: To analyse the accordance between CBP measured by the Sphygmocor® and by echotracking.

Materials and Methods: CBP measurements were performed on 115 patients of the unit. Applanation tonometry was performed on radial artery and CBP was estimated by the onboard transfer function of the Sphygmocor®. Echotracking measurements were performed on right CCA (ART.LAB) and treated to obtain Systolic Blood Pressure (SBP) and Pulse Pressure (PP). Pearson's correlation and Bland and Altman graph were performed.

Results: We showed a 14 mmHg overestimation of central SBP and PP by echotracking compared to applanation tonometry.

The correlations between central BP estimated by transfer function and systolic blood pressure calculated by echotracking were good (SBP: $R^2=0,81$; PP: $R^2=0,66$, $p<0.001$).

Conclusion: This study has shown a good agreement between the two techniques to calculate central SBP in spite of a 14 mmHg overestimation by echotracking. As applanation tonometry has been shown to underestimate central pressure, echotracking could be the best technique to measure it. But more patients should be performed.

P2.03

COMPARISON OF COMMON CAROTID ARTERY DISTENSION WAVE WITH TONOMETRY FOR CENTRAL PULSE PRESSURE ASSESSMENT

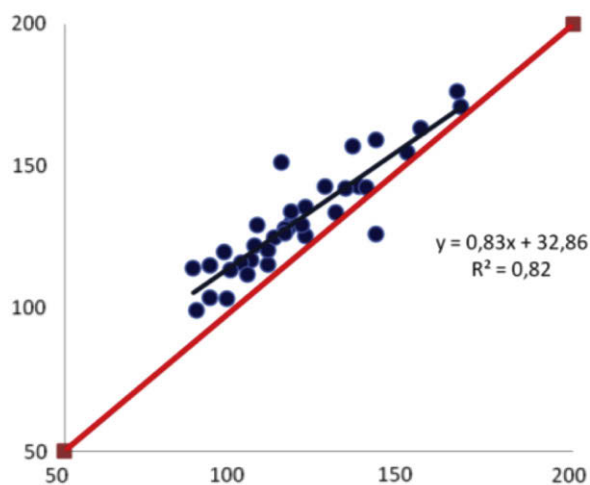
A. Bertaux, E. Bozec, S. Laurent, P. Boutouyrie
Université René Descartes, INSERM U970, APHP, Paris, France

Aims. Measurement of central blood pressure remains difficult. Also a good proxy for aortic pressure, carotid pressure is difficult to get through tonometry. Moreover, tonometry being a contact method, motion of the wall, especially if large, might alter the pressure waveform. We thus compared echotracking carotid distension waveforms with radial derived aortic waveforms for assessment of central pulse pressure.

Methods: We included 115 subjects aged 18-75 with valid carotid echotracking (ET) (Artlab, Esaote, NL) and radial derived aortic waveforms (TO) (Sphygmocor, Atcor, Aus). Central SBP and PP were compared with correlations and Bland-Altman method. ET was calibrated using radial mean and diastolic blood pressure

Results: Correlation equation for SBP was $ET-SBP=0.83*TO-SBP+32.9$, $R^2=0.82$. Correlation equation for PP was $ET-PP=0.80*TO-PP+21.5$, $R^2=0.71$. Mean bias for SBP was -12 ± 8 mmHg and -12 ± 7 mmHg for PP.

Echotraking SBP (mmHg)



Tonometry SBP (mmHg)

Conclusion: Although waveforms appeared very similar and correlation were very narrow, there was a systematic overestimation of SBP and PP by echotracking, compared to tonometry. Whether this is overestimation by ET or underestimation by TO remains to be demonstrated

P2.04

PULSE WAVE VELOCITY AND WAVE INTENSITY IN THE CAROTID ARTERY OF HEALTHY HUMAN: WINDKESSEL AND WINDKESSEL-LESS ANALYSIS

A. Borlotti¹, S. Vermeersch², E. R. Rietzschel², M. L. De Buyzere², P. Segers², A. W. Khir¹

¹Brunel University, London, United Kingdom

²Ghent University, Ghent, Belgium

Pulse wave velocity (PWV) is an acknowledged marker to arterial compliance. A time-domain approach to study wave propagation taking into account the Windkessel effects in arteries was introduced (1). The model assumes that the measured pressure (P) and velocity (U) are the sum of two components; a reservoir (P_r , U_r) due to the buffering capacity of arteries and an excess (P_e , U_e) due to the waves. A direct comparison of PWV and wave intensity (WI) with and without considering P_r is lacking and quantifying the differences constitutes the objective of this work.

We measured P and U in the carotid artery of 328 healthy human subjects (45 ± 6 years old); a subset of the Asklepios study to examine pulse velocity and intensity with (PWV and WI) and without (PWV_e and WI_e) the Windkessel effects. PWV is 45% higher than PWV_e (8.4 ± 2.4 vs. 5.8 ± 2.0 m/s, $p<0.001$). The intensities of the forward and backward compression waves of WI are 35% and 166% higher than those of WI_e (21.8 ± 8.0 vs. 16.2 ± 7.1 W/m² and 3.2 ± 2.5 vs. 1.2 ± 0.9 W/m², $p<0.001$).

Values of pulse wave velocity and intensities vary massively depending on whether P_r is taken into account. A P_r -independent methods for calculating these parameters are needed to determine the relative accuracy and importance of P_r .

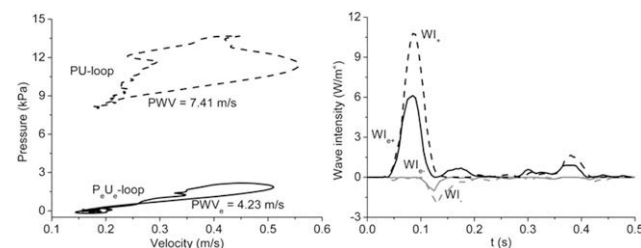


Figure 1 Wave speed (left) and intensity (right) using the Windkessel and Windkessel-less analysis.

(1) Wang J.J. et al. Time-domain representation of ventricular-arterial coupling as a windkessel and wave system. American Journal of Physiology - Heart and Circulatory Physiology 2003;284(4 53-4):H1358-H1368.

P2.05

INVESTIGATION OF FLOW AND WALL SHEAR STRESS DURING PULSATILE FLOW IN A HUMAN AORTA WITH A COARCTATION AND POST-STENOTIC DILATION USING LARGE EDDY SIMULATIONS

R. Gärdhagen, M. Karlsson
Linköping University, Linköping, Sweden

Flow field and wall shear stress (WSS) in an idealized model of a human aorta with a coarctation and a post-stenotic dilatation, Figure 1, were investigated with large eddy simulation. A physiologic pulse was prescribed at the inlet, Figure 1. Phase averages of axial WSS, from 30 consecutive pulses, were determined between the throat ($x=0$) and the exit ($x=0.2$ m) along lines where the x-y plane and x-z plane cross the vessel wall. Figure 2 shows these values at late systole; the pattern is representative for the entire systolic phase. WSS peaks in the stenosis, as expected, but also at the end of the dilatation ($x=0.06$ m). In the dilatation backflow causes a negative peak. Diastolic WSS is characterised by low amplitude oscillations. Also noticeable is the asymmetric pattern between the inner ($y>0$) and outer ($y<0$) sides caused by the flow through the arch. Thus, large spatial, temporal, and probably asymmetric WSS gradients in the already diseased region suggest increased risk for further endothelial dysfunction [1]. This reflects a complex, partly turbulent, flow pattern that may disturb the blood flow in the abdominal aorta.

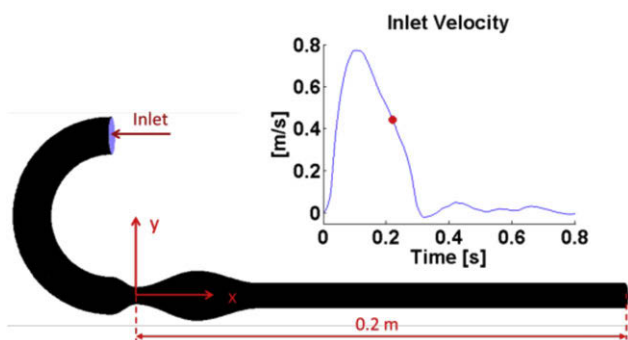


Figure 1 Geometry with flow direction and inlet pulse profile.

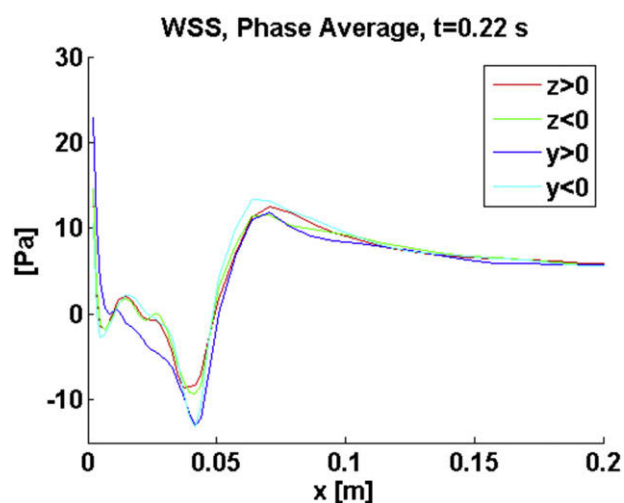


Figure 2 Phase averaged axial WSS along four lines between the throat ($x=0$) and the exit ($x=0.2$ m).

References

- [1] Kleinstreuer, C. and Lei, M. and Archie, J.P. Jr., "Flow input waveform effects on the temporal and spatial wall shear stress gradients in a femoral graft-artery connector", *J Biomech Eng.*, Vol. 118, No 4, 506-510, 1996.

P2.06

RETINAL PULSE WAVE VELOCITY ASSESSMENT FOR IN-VIVO ESTIMATION OF MICROCIRCULATORY ARTERIAL STIFFNESS IN MEDICALLY VALIDATED HEALTHY VOLUNTEERS

K. Kotliar^{1,2}, M. Baumann², A. Djimandjaja², I. Lanzl³, M. Halle⁴, U. Heemann², A. Schmidt-Trucksäss⁵

¹Institute of Micro Technology and Medical Device Technology (MIMED), Technische Universität München, München, Germany

²Department of Nephrology, Technische Universität München, München, Germany

³Department of Ophthalmology, Technische Universität München, München, Germany

⁴Department of Preventive Sports Medicine, Technische Universität München, München, Germany

⁵Division of Sports Medicine, University of Basel, Basel, Switzerland

A novel clinical methodology is proposed, which characterizes in-vivo arterial stiffness in the central microcirculation. Pulse wave propagation in retinal arteries is assessed and a parameter "retinal pulse-wave velocity" (rPWV) is calculated. We demonstrated previously that both aging with not excluded cardiovascular risk factors and mild arterial hypertension are associated with elevated rPWV. Whether rPWV increases with age in a cohort of medically

validated healthy subjects is investigated. 71 healthy 41.0±12.1 (range: 20 – 66) years old volunteers were examined. The following cardiovascular risk factors were excluded: overweight, increased blood pressure, cholesterol level and blood glucose. Time dependent alterations of vessel diameter were assessed by the Dynamic Vessel Analyzer in a segment of a retinal artery. The data was filtered and evaluated by methods of mathematical signal analysis in order to obtain rPWV value. rPWV amounted to 370±100 (range: 180 – 620) units/second in the whole group (units correspond to μm in the Gullstrand's eye model). In the cohort rPWV increased with age (Pearson's correlation: $r=0.41$, $p<0.005$) to 21 units/second per a decade. rPWV showed weak correlations with vessel diameter: $r=-0.27$, $p<0.05$ and mean arterial pressure: $r=0.22$, $p<0.05$. Thus healthy aging with excluded mentioned cardiovascular risk factors is associated with a flat increase of rPWV and hence with age-related elevation of retinal arterial stiffness. This rPWV alteration and absolute rPWV values in medically validated volunteers allow to distinguish this cohort well from young hypertensives (1620±1310 units/second) or aged subjects with not excluded cardiovascular risk (1200±520 units/second) reported in our previous studies.

P2.07

CENTRAL HEMODYNAMIC ESTIMATES BY ULTRASOUND-DERIVED CAROTID DISTENSION WAVEFORMS: COMPARISON WITH APPLANATION TONOMOMETRY

C. Palombo¹, N. Guraschi², C. Morizzo¹, G. Bini¹, M. Kozakova^{1,2}

¹University of Pisa, Pisa, Italy

²Esaote SpA, Genova, Italy

Background: new commercially available radiofrequency (RF) based ultrasound (US) allows accurate depiction of common carotid (CCA) distension waveforms, whereas carotid applanation tonometry represents a validated technique for pressure waveform description. From both distension and pressure waveforms local carotid pressure and some hemodynamic indices, such as Left Ventricular Ejection Time (LVET), are obtained. Aim of this study was to validate estimates of local CCA pressure and LVET by ultrasound distension waveforms against applanation tonometry.

Methods: in 112 subjects (66 males; mean age 56.2±9.9; 16 non diabetic non hypertensive, NL; 34 hypertensives, HT; 62 diabetics, DM), right CCA distension waveforms were obtained by RF-based wall tracking of the near and far wall (MyLab70, Esaote). Afterwards, CCA pressure waveforms were recorded by applanation tonometry (Pulsepen, Diatecne). Local systolic, diastolic and pulse pressure were derived calibrating both waveforms for brachial pressure (Omron) as previously described (Van Bortel LM et al, *J Hypertens* 2001). LVET was also evaluated with both systems.

Results: brachial SBP and PP were 137.0±17.1 and 57.4±13.9 mmHg, significantly higher ($p<0.001$) than those recorded by tonometry or US. Brachial DBP was 79.6 ± 8.9 mmHg. US-derived SBP, DBP and PP were slightly but significantly higher than tonometric values, while LVET was lower (see Table).

| Method | SBP (mmHg) | DBP (mmHg) | PP (mmHg) | LVET (ms) |
|------------|--------------|------------|-------------|-----------|
| Tonometry | 121.3±15.8 | 77.9±9.2 | 43.5±13.1 | 317±27 |
| Ultrasound | 126.6±16.6** | 79.6±8.7** | 46.9±13.8** | 297±25** |

** : $p<0.01$ for US vs Tonometry.

However, corresponding measures obtained with the two techniques were well correlated (r values from 0.754 and 0.896, $p<0.001$). In Bland-Altman analysis, the outliers were between 4 and 6 for each parameter.

Conclusions: RF-US allows accurate estimate of central BP and LVET.

P2.08

CENTRAL-TO-PERIPHERAL BLOOD PRESSURE AMPLIFICATION: INVASIVE VALIDATION OF TWO DEVICES (SPHYGMOCOR AND OMRON HEM9000AI)

G. Pucci¹, F. Battista¹, S. Notaristefano², C. Cavallini², E. Mannarino³, G. Schillaci¹

¹Unit of Internal Medicine, University of Perugia, Terni, Italy

²Cardiology Department, Perugia Hospital, Perugia, Italy

³Internal Medicine, Angiology and Atherosclerotic Diseases, University of Perugia, Perugia, Italy

Introduction: central-to-peripheral systolic blood pressure (SBP) and pulse pressure (PP) amplification (SBP-amp, PP-amp) are independent